

BMJ Open Observational study of clinical characteristics of dome-shaped macula in Chinese Han with high myopia at Zhongshan Ophthalmic Centre

Xiujuan Zhao, Xiaoyan Ding, Cancan Lyu, Shiyi Li, Yu Lian, Xiaohong Chen, Silvia Tanumiharjo, Aiyuan Zhang, Jing Lu, Xiaoling Liang, Chenjin Jin, Lin Lu

To cite: Zhao X, Ding X, Lyu C, *et al*. Observational study of clinical characteristics of dome-shaped macula in Chinese Han with high myopia at Zhongshan Ophthalmic Centre. *BMJ Open* 2018;**8**:e021887. doi:10.1136/bmjopen-2018-021887

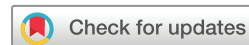► Prepublication history for this paper is available online. To view these files, please visit the journal online (<http://dx.doi.org/10.1136/bmjopen-2018-021887>).

XZ and XD contributed equally.

Received 24 January 2018

Revised 10 August 2018

Accepted 8 November 2018



© Author(s) (or their employer(s)) 2018. Re-use permitted under CC BY-NC. No commercial re-use. See rights and permissions. Published by BMJ.

State Key Laboratory of Ophthalmology, Zhongshan Ophthalmic Center, Sun Yat-sen University, Guangzhou, Guangdong, China

Correspondence to

Professor Lin Lu;
lulin@gzoc.com

ABSTRACT

Purpose To evaluate the prevalence of dome-shaped macula (DSM) in highly myopic eyes among Chinese Han and to detect the correlation with myopic maculopathy and macular complications.

Methods A total of 736 Chinese Han patients (1384 eyes) with high myopia (refractive error ≤ 6.0 diopters or axial length ≥ 26.5 mm) are reviewed based on information entered into a high-myopia database at Zhongshan Ophthalmic Centre. Subfoveal choroidal thickness (SFCT) and parafoveal choroidal thickness (PFCT) are measured. The prevalence of DSM in patients with myopic maculopathy is categorised from C0 to C4. Clinical features, including macular complications, SFCT and PFCT, are compared between myopic eyes with and without DSM.

Results Among the 1384 eyes, 149 (10.77%) show DSM. In highly myopic eyes without macular complications, the best corrected visual acuity is significantly worse in patients with DSM ($p=0.002$), and the ratio between subfoveal and parafoveal choroidal thickness (S/PCT) is significantly elevated in patients with DSM ($p=0.021$). The proportion of foveal schisis (17.24% vs 62.86%) is much lower in eyes with DSM compared with those without DSM. However, the proportions of extrafoveal schisis (39.66% vs 5.37%), foveal serous retinal detachment (SRD) (5.17% vs 0) and epiretinal membrane (ERM) (24.14% vs 10.74%) are much higher in eyes with DSM. The proportion of DSM was lower in C0 and C1, but higher proportion of DSM was found in C3 and C4.

Conclusions DSM is found in 10.77% of highly myopic eyes among Chinese Han. DSM might be a protective mechanism for foveal schisis and a risk factor for extrafoveal schisis, SRD and ERM.

INTRODUCTION

Gaucher *et al* first described the dome-shaped macula (DSM) as a morphologic feature in 2008 by characterising it as an inward convexity or anterior deviation of the macula using optical coherence tomography (OCT).¹ Although recent advances in OCT technology have helped to evaluate DSM, its physiopathology remains uncertain. Scleral

Strengths and limitations of this study

- The study discusses DSM in the Chinese Han population, reports the prevalence of eight macular complications and its relation to choroidal changes.
- The study compared the demographic characteristics between highly myopic eyes with and without DSM.
- The sclera thickness, whose role in the formation of DSM has been hypothesised, was not investigated because the outer scleral border would be difficult to visualise in some cases, even if we used an spectral domain - optical coherence tomography in enhanced depth imaging modality.

infolding through the collapse of the posterior portion of the eye wall or vitreomacular traction were initially proposed as causes of DSM.² Subsequently, DSM was thought to be secondary to an ingrowth of the choroid, but recent research indicates that the main problem is focal scleral thickening in the foveal area.³ However, the prevalence, clinical features and mechanisms of this disease are still controversial.

Although DSM has been described in Western countries and Japan, the clinical features of DSM are poorly documented in China. This study aims to analyse the frequency and morphologic features of DSM in a large series of highly myopic Chinese Han patients. The prevalence of DSM, the rate of myopic maculopathy and macular complications, such as foveal schisis, extrafoveal schisis, serous retinal detachment (SRD), epiretinal membrane (ERM), full thickness macular holes (FTMH), lamellar macular hole (MH), choroidal neovascularization (CNV) and macular haemorrhage, are compared between eyes with and without DSM.

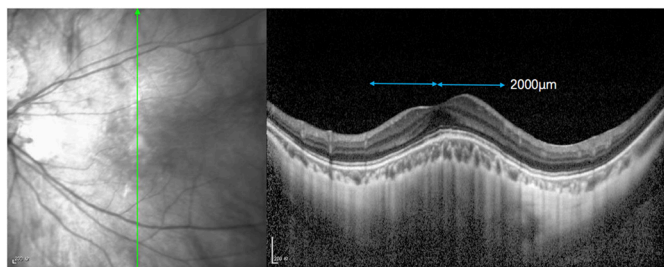


Figure 1 Measurement protocol from horizontal and vertical scans obtained with spectral-domain optical coherence tomography (SD-OCT) in eyes with dome-shaped macula (DSM) configuration. The retinal and choroidal thickness were measured at subfoveal and at point 2000 μm superior, nasal, temporal and inferior to the fovea.

METHODS

The medical records of 736 consecutive highly myopic patients totalling 1472 eyes were reviewed at the High Myopia Clinic at Zhongshan Ophthalmic Center from January 2014 to July 2016. High myopia was defined as a refractive error of ≤ -6.0 diopters and axial length (AL) of ≥ 26.5 mm. Eighty-eight eyes (5.98%) were excluded due to AL less than 26.5 mm (12 eyes), rhegmatogenous retinal detachment (53 eyes) and poor-quality OCT images (23 eyes). Thus, 1384 eyes were enrolled in this study.

Comprehensive ocular examinations were performed in all participants. Spherical equivalent refraction (SER) was measured using an autorefractometer (KR-8900 version 1.07, Topcon Corporation, Tokyo, Japan) after complete cycloplegia for both eyes. Best-corrected visual acuity (BCVA) was determined with Snellen VA charts and was converted to the logarithm of the minimal angle of resolution (logMAR) for statistical analysis. AL was recorded using the IOL Master (Carl Zeiss, Tubingen, Germany) and fundus photographs (FP) were obtained using a TRC50LX (Topcon). OCT images were obtained with a spectral-domain OCT (SD-OCT, Heidelberg Engineering, Heidelberg, Germany) by a single experienced examiner who was masked to the clinical diagnosis. Vertical and horizontal scans that passed through the centre of the fovea and raster scans, which cover all the macular complications were obtained in each eye.

Two experienced retinal specialists (XZ and XD) read all of the FP and OCT. The presence of myopic maculopathy was defined and classified based on the International Photographic Classification and Grading System for Myopic Maculopathy.⁴ Eight macular complications were identified, including foveal schisis, extrafoveal schisis, SRD, ERM, FTMH, lamellar MH, CNV and macular haemorrhage. All cases of CNV were diagnosed through a combination of OCT and FFA. DSM was defined as the presence of an inward bulge of the macular retinal pigment epithelium (RPE) of $>50 \mu\text{m}$ in the vertical, horizontal direction or both, and was diagnosed with an OCT image according to the method designed by Ellabban and Ohsugi *et al.*^{5 6} ERM was defined as an avascular,

fibrocellular membrane on the inner retinal surface.⁷ FTMH was characterised by a vertical split in the neurosensory layers of foveal region. Lamellar MH was defined as a partial thickness defect of the macular area, with an irregular foveal contour and a schisis between inner and outer retinal layers, with intact photoreceptors.⁸ The choroidal thickness (CT) was measured from the outer portion of the hyper-reflective line that corresponded to the RPE to the inner surface of the sclera using a single masked author.⁹ Measurements were taken of the parafoveal choroid at 2 mm superiorly, inferiorly, temporally and nasally to the fovea using a built-in calibre tool (figure 1). The average value from these four locations is defined as the parafoveal choroidal thickness (PFCT). The ratio of the subfoveal to the parafoveal CT (S/PCT) was also calculated.

STATISTICAL ANALYSIS

Age, SER, AL, BCVA, and ratios of subfoveal and parafoveal CT were compared between the two groups using independent sample *t*-tests. The subfoveal and parafoveal CT between the groups were compared using multiple linear regressions that paired the eyes based on AL, age and SER. The incidences of various macular complications and the distribution of myopic maculopathy between the groups were compared using χ^2 tests or Fisher exact probability tests. A *p* value of <0.05 was considered statistically significant.

Patient and public involvement

No patients or the public were involved in the study protocol design, the specific aims or the research questions, and the plans for the design or implementation of the current study. No patients or the public were involved in the interpretation of the results of the study or preparation of the manuscript. There are no plans to disseminate the results of the research to study participants.

RESULTS

Out of the 1384 eyes, DSM was identified in 10.77% (149/1384), while 1235 highly myopic eyes without DSM served as the control. OCT imaging of the posterior pole showed that there were 88 horizontal oval-shaped DSM, nine vertical oval-shaped DSM and 33 DSM with the shape of a round dome. No significant differences were observed based on gender, age, SER or AL between eyes with DSM and without DSM (table 1). Furthermore, there was no significant difference in BCVA (0.67 ± 0.57 vs 0.55 ± 0.56 , $p=0.464$). The subfoveal CT tended to be thinner in the DSM group (60.10 ± 46.61 vs 73.81 ± 53.54), but the difference was not significant ($p=0.064$). Moreover, the ratio between the subfoveal and parafoveal CT showed no difference between the two groups (1.17 ± 0.72 vs 0.97 ± 0.76 , $p=0.073$).

Since macular complications, such as CNV, macular holes and foveal schisis, are highly associated with

Table 1 Demographic characteristics of the 1384 highly myopic eyes

	DSM		P value
	Present (n=149)	Absent (n=1235)	
AL (mm±SD)	30.76±1.92	29.33±1.99	0.991
Sex (M/F)	55/93	221/426	0.489
Age (years±SD)	50.33±14.81	47.73±13.93	0.310
SER (SER±SD)	-17.42±5.30	-15.93±6.49	0.854
BCVA (logMAR±SD)	0.67±0.57	0.55±0.56	0.464
SFCT (μm±SD)	60.10±46.61	73.81±53.54	0.064
PFCT (μm±SD)	58.71±46.40	83.19±50.10	0.074
SF/PF	1.17±0.72	0.97±0.76	0.073

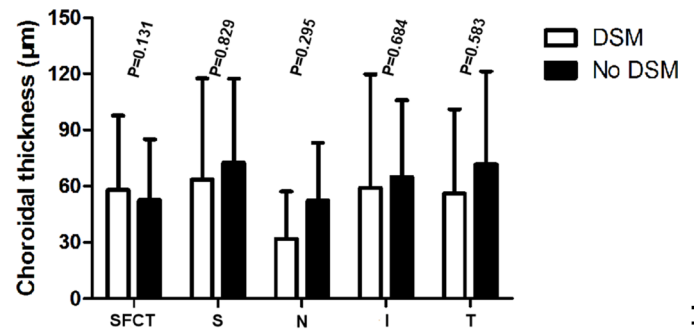
AL, axial length; BCVA, best corrected visual acuity; DSM, dome-shaped macula; F, female; M, male; PFCT, parafoveal choroidal thickness; SER, spherical equivalent refraction; SFCT, subfoveal choroidal thickness.

impairment of visual function and the choroidal structure, the potential effect of DSM might be sheltered by these complications. In order to clarify the correlation between DSM and BCVA and choroidal thickness, eyes with macular complications, such as foveal schisis, extrafoveal schisis, SRD, ERM, FTMH, lamellar MH, CNV, macular haemorrhage and macular atrophy, were excluded in the subgroup analysis. Thus, 67 DSM eyes and 692 control eyes with the absence of macular complications were enrolled (table 2). Notably, the BCVA was much worse in DSM eyes compared with the control eyes (0.35 ± 0.36 vs 0.55 ± 0.51 , $P=0.002$). Again, the subfoveal CT showed no statistical difference between the two subgroups (69.04 ± 52.05 vs 84.53 ± 57.94 , $p=0.217$)

Table 2 Comparison of eyes with and without DSM in 759 myopic eyes with normal macular architecture

	DSM		P value
	Present (n=67)	Absent (n=692)	
Age	45.60±15.27	43.09±13.61	0.53
AL	30.66±2.04	29.38±2.07	0.869
SER	-17.48±5.23	-14.28±5.88	0.958
BCVA	0.55±0.51	0.35±0.36	0.002
SFCT	69.04±52.05	84.53±57.94	0.217
PFCT	66.09±52.42	94.80±52.78	0.586
SF/PF	1.16±0.62	0.93±0.48	0.021
SF/S	1.03±0.69	0.85±0.58	0.189
SF/I	1.47±1.25	0.96±0.57	0.000
SF/N	2.08±1.19	1.59±1.05	0.203
SF/T	1.24±0.93	0.95±0.82	0.016

AL, axial length; BCVA, best corrected visual acuity; DSM, dome-shaped macula; I, inferior; N, nasal; PFCT, parafoveal choroidal thickness; S, superior; SER, spherical equivalent refraction; SFCT, subfoveal choroidal thickness; T, temporal.

**Figure 2** Comparison of dome-shaped macula (DSM) and non-DSM choroidal thickness in highly myopic eyes without macular complications.

(figure 2). The mean parafoveal CT was $66.09\pm52.42\mu\text{m}$ in the DSM group and $94.80\pm52.78\mu\text{m}$ in the control group ($p=0.586$). However, the ratio of subfoveal and parafoveal CT was significantly elevated in the DSM group (1.16 ± 0.62 vs 0.93 ± 0.48 , $p=0.021$). Moreover, the ratio of inferior and temporal CT were significantly elevated in the DSM group (1.47 ± 1.25 vs 0.96 ± 0.57 , $p<0.001$; 1.24 ± 0.93 vs 0.95 ± 0.82 , $p<0.001$), and there was no difference in superior CT (1.03 ± 0.69 vs 0.85 ± 0.58 , $p=0.189$) or nasal CT (2.08 ± 1.19 vs 1.59 ± 1.05 , $p=0.203$).

No significant differences were observed based on age, AL, SER and BCVA between eyes with DSM and without DSM with macular complications. The rate of macular complications was also compared between patients with and without DSM. Overall, the prevalence of complications was not significantly different in eyes with DSM compared with eyes without DSM (38.93% vs 36.19%, $p=0.513$). The proportion of foveal schisis (17.24% vs 62.86%, $p<0.001$) was significantly lower in eyes with DSM compared with eyes without DSM, while foveal SRD (5.17% vs 0%, $p=0.001$), extrafoveal schisis (39.66% vs 5.37%, $p<0.001$) and ERM (24.14% vs 10.74%, $p=0.007$) were significantly more frequent in eyes with DSM compared with those without DSM. However, there was no significant difference in the proportion of FTMH (3.45% vs 10.74%, $p=0.130$), lamellar MH (3.45% vs 0.89%, $p=0.144$), CNV (5.17% vs 7.16%, $p=0.785$) and macular haemorrhage (1.72% vs 2.24%, $Pp=0.801$) (table 3).

The severity of myopic maculopathy was also determined in all 1384 eyes. The fundus was unremarkable in 91 eyes (C0), as was the tessellated fundus in 411 eyes (C1), diffuse chorioretinal atrophy in 668 eyes (C2), patchy chorioretinal atrophy in 94 eyes (C3) and macular atrophy in 120 eyes (C4). DSM was observed in each stage of myopic maculopathy from C0 to C4. The proportion of DSM was lower in C0 and C1, but higher proportion of DSM was found in C2–C4. (table 4).

DISCUSSION

To our knowledge, this study includes one of the largest sample size of DSM. Our results show that DSM is found in 149 out of 1384 (10.77%) highly myopic eyes in

Table 3 Comparison of eyes with and without DSM in 505 myopic eyes with macular complications

	DSM		P value
	Present (n=58)	Absent (n=447)	
Age	57.95±12.47	54.64±11.02	0.084
AL	30.92±1.74	29.22±1.83	0.974
SER	-17.31±5.46	-13.78±6.38	0.953
BCVA	0.82±0.62	0.88±0.67	0.420
Foveal schisis	10/58 (17.24%)	281/447 (62.86%)	0.000
Extrafoveal schisis	23/58 (39.66%)	24/447 (5.37%)	0.000
Foveal SRD	3/58 (5.17%)	0/447 (0%)	0.001
ERM	14/58 (24.14%)	48/447 (10.74%)	0.007
FTMH	2/58 (3.45%)	48/447 (10.74%)	0.130
Lamellar MH	2/58 (3.45%)	4/447 (0.89%)	0.144
CNV	3/58 (5.17%)	32/447 (7.16%)	0.785
Macular haemorrhage	1/58 (1.72%)	10/447 (2.24%)	0.801

CNV, choroidal neovascularization; DSM, dome-shaped macula; ERM, epiretinal membrane; FTMH, full thickness macular hole; MH, macular hole; SER, spherical equivalent refraction; SRD, serous retinal detachment

hospital-based Chinese Han. This ratio is similar to other hospital-based researches, for example, rate of 10.7% reported by Gaucher *et al.*¹ as well as Chebil *et al.*¹⁰ who found DSM in 24 out of 200 highly myopic eyes (12.0%) and Garcia-Ben¹¹ who found DSM in 28 out of the 260 (10.7%) pathologically myopic eyes. However, DSM was observed in as much as 20.1% (225/1118) of Japanese subjects examined by Liang *et al.*¹² The differences in the inclusion criteria used in these studies may explain the variations in their findings. In Liang's study, the SER was ≤8.0 diopters or axial length of ≥26.5 mm, which results in a narrower spectrum with a higher and more extensive myopia population. However, excluding the effect

Table 4 Correlation of DSM and myopic maculopathy

Myopic maculopathy	DSM		P value
	Present (n=149)	Absent (n=1235)	
Category 0 (no macular lesions)	1/149 (0.67%)	90/1235 (7.29%)	0.001
Category 1 (tessellated fundus only)	20/149 (13.42%)	391/1235 (31.66%)	0.000
Category 2 (diffuse chorioretinal atrophy)	86/149 (57.72%)	582/1235 (47.13%)	0.015
Category 3 (patchy chorioretinal atrophy)	18/149 (12.08%)	76/1235 (6.15%)	0.007
Category 4 (macular atrophy)	24/149 (16.11%)	96/1235 (7.77%)	0.001

DSM, dome-shaped macula

of the patient selection bias, the prevalence of DSM in Liang's study was still higher when compared with other studies. Furthermore, other studies performed with small Japanese sample sizes reveal a relative low rate of DSM, at approximately 10%. For example, Ohsugi *et al* reported a DSM rate of 9.3%.⁶ Therefore, considering the patient selection bias, we suggest that the prevalence of DSM in high myopia populations is nearly consistent across ethnic groups worldwide. Notably, all of the documented data, including the present study, came from hospital-based patients and were clinically based studies. It is difficult to assess precisely the prevalence of DSM in the general population. Therefore, further population-based epidemiological studies are desirable to explore the real incidence of DSM.

Variations in CT are considered related to the evolution of DSM and its associated complications. The results thus far have been quite controversial. For instance, it is not clear if the choroid is thickened, normal or atrophic in eyes with DSM. Some studies show a thickened choroid in DSM,^{3 10} especially in eyes with SRD,¹³ while others show that choroidal thickness decreases in DSM.⁵ Some authors have recently suggested that thinning of the choroid is secondary to the elongation of the posterior staphyloma, or secondary to the sclera thickening. Furthermore, Cailiaux *et al*¹⁴ show that the subfoveal choroid is thicker than the parafoveal choroid. The current study does not find any significant differences in either SFCT or PFCT between myopic eyes with and without DSM in both the overall population and the subgroup without other macular complications, while the ratio of subfoveal to parafoveal choroid appears to be significantly larger in patients with DSM without other complications. This was in accordance with the results reported by Ellabban *et al*¹⁵ who performed a longitudinal study that demonstrated a progressive thinning of the choroid and sclera in eyes with DSM in the paramacular area. Our results suggest that the thinning of the choroid occurs mainly outside the macular region in eyes with DSM, thus resulting in what appears to be a localised relative thickening of the sclera. The central macular choroidal area is preserved in eyes with DSM, while the paramacular choroid appears to be pathological.

In the current study, DSM is highly associated with the severity of myopic maculopathy, which is remarkable. According to meta analyses of pathologic myopia (META-PM) study, myopic maculopathy is defined as C0–C4 from no macular lesions to macular atrophy, respectively. Categories 2 and above are classified as pathologic lesions, while Categories 1 and below are considered unremarkable.⁴ Our data shows that DSM can be seen at any stage of myopic maculopathy, and the proportion of DSM increases with the progression of maculopathy. Only 1.10% and 4.87% of eyes with DSM fall into Categories 0 and 1, respectively, while 12.87% fall into Category 2, and 19.15% and 20.00% fall into Categories 3 and 4, respectively. To our knowledge, this is the first study to focus on the correlation between DSM and myopic

maculopathy. These data show that DSM is not rare in eyes with advanced maculopathy; however, more careful OCT examinations are warranted to identify the particular entity. Furthermore, this study shows a dramatic increase in the prevalence of DSM between non-pathological category 1 and pathological category 2. Our data provides novel clinical evidence for the definition and classification of pathological maculopathy.

Besides myopic maculopathy, potential vision-threatening macular complications, such as SRD, FTMH, LMH, foveal schisis and extrafoveal schisis, are well-established complications in DSM, dependently or independently. Interestingly, foveal schisis (17.24% vs 62.86%, $p < 0.001$) is less frequent in groups with DSM compared with those without, while extrafoveal schisis (39.66% vs 5.37%, $p < 0.001$), SRD (5.17% vs 0, $p = 0.001$) and ERM (24.14% vs 10.74%, $p = 0.007$) are more frequent in those with DSM compared with those without DSM. On the other hand, the rate of FTMH, lamellar MH, CNV and macular haemorrhage showed no significant differences between the two groups. Interestingly, FTMH with DSM was reported to be stable for 3–5 years without progression to retinal detachment even with extremely high myopia. The indentation effect induced by the DSM may prevent FTMH from progressing.¹⁶ Our data suggests that DSM might be a protective factor of foveal schisis, but a risk factor for extrafoveal schisis, SRD and ERM, which was consistent with García-Ben *et al.*¹⁷ García-Ben *et al* reported that the protective effect in patients with DSM by reducing the AL. However, in our study, the AL was longer in patients with DSM than those without DSM. It is well documented that foveal schisis is mostly due to tangential and perpendicular vitreomacular traction. We speculate that the dome might play a role in reducing mechanical damage in the foveal area, but it may exaggerate the perpendicular vitreomacular traction in the parafoveal area as a result. Our data supports the hypothesis that passive resistance of the macular sclera occurs during the elongation of the peripheral staphyloma, thus providing new understanding of the mechanisms of DSM.

SRD is extremely rare (3 eyes out of 149, 2.01%) in our study. Interestingly, the prevalence of SRD (sometimes called subretinal fluid, foveal detachment or neuroretinal detachment in previous studies) ranges from 9.7% to 69%¹¹⁰ and is considered one of the major complications of DSM in Western countries. SRD is present in 10 out of 15 eyes in the first study with DSM¹ and 52.1% (25 of 48 eyes) in the later study with the same group¹⁴ even after ruling out SRD due to CNV. On the other hand, the prevalence of SRD is dramatically low in Asia (5.9% or 3 out of 51 patients)⁵ and even lower in studies with large sample sizes.¹² The dramatic discrepancy in the frequency of SRD in DSM patients among ethnic populations is still elusive. Interestingly, in Imamura's study, patients are seen either in New York or Fukushima and the ethnic background of the patients with DSM is not mentioned.³ The study shows a moderate rate of SRD with 8.70% (2 out of 23 patients), which seems to provide more evidence that

there is a discrepancy in prevalence of SRD between different ethnic groups.

Although SRD complicates a large proportion of DSM cases, its causes are poorly understood. Imamura *et al*³ hypothesise that SRD could result from the obstruction of outflow of choroidal fluid due to a thick sclera. However, others have noted that the submacular choroid is abnormally thick in eyes with SRD for this degree of myopia, thus suggesting a mechanism similar to central serous chorioretinopathy.¹³ Furthermore, the mean dome height is much higher in the study by Caillaux *et al*, and the difference in the dome height could be one of the causes of serious RD. Fortunately, the SRD has a relatively benign natural history in Western studies.¹⁸ In Suadier's study of 29 cases, SRD is present initially in 15 of 29 eyes, increases in four cases and is resolved spontaneously in seven cases.¹⁸

This study has several limitations. First, this is a retrospective case study, and the potential inherent limitations are associated with the study's design. Second, the sclera thickness, whose role in the formation of DSM has been hypothesised, was not investigated because the outer scleral border would be difficult to visualise in some cases, even if we used an SD-OCT in enhanced depth imaging modality. Third, CT measurements were carried out manually using a built-in calliper. Further investigations using swept-source OCT, which allows for deeper tissue penetration into the choroid and the sclera with automatic measurement, would be beneficial. Despite these limitations, this is the first study to examine DSM among the Chinese Han population, and it is one of the largest case study of highly myopic patients with DSM.

In conclusion, DSM is a frequent subtype found in 10.77% of patients with high myopia. Visual acuity is compromised in eyes with DSM compared with those without DSM. A comparison of highly myopic patients with and without DSM shows differences with Western populations, while SRD remains a rare complication of DSM, at least in Asian populations. DSM may be a protective mechanism for foveal schisis, but it is positively associated with extrafoveal schisis, SRD and ERM.

Contributors LL conceived the aims and overall design of the study. XZ and XD acquired the data and did the writing of the different sections, tables and figures. CL, SL, CJ and XL did the literature search and statistical analyses, XC, YL, ST, AZ and JL collected the data used in the study. All authors were involved in the study design, data analyses, data interpretation and revision of the paper. The following authors had access to the full raw data set: LL and XZ. The corresponding author had the final responsibility to submit for publication.

Funding Supported by Fundamental Research Funds of State Key Laboratory of Ophthalmology, National Natural Science Foundation of China (81570862) and Guangzhou Science and Technology Project (2014Y2-00064) and Guangdong Provincial Science and Technology Grant (2016A020215096).

Competing interests None declared.

Patient consent for publication Not required.

Ethics approval Zhongshan Ophthalmic Center Ethics Committee.

Provenance and peer review Not commissioned; externally peer reviewed.

Data sharing statement Extra data can be accessed via the Dryad data repository at <http://datadryad.org/with the doi: 10.5061/dryad.h544560>.

Open access This is an open access article distributed in accordance with the Creative Commons Attribution Non Commercial (CC BY-NC 4.0) license, which permits others to distribute, remix, adapt, build upon this work non-commercially, and license their derivative works on different terms, provided the original work is properly cited, appropriate credit is given, any changes made indicated, and the use is non-commercial. See: <http://creativecommons.org/licenses/by-nc/4.0/>.

REFERENCES

1. Gaucher D, Erginay A, Lecleire-Collet A, *et al*. Dome-shaped macula in eyes with myopic posterior staphyloma. *Am J Ophthalmol* 2008;145:909–14.
2. Mehdizadeh M, Nowroozzadeh MH. Dome-shaped macula in eyes with myopic posterior staphyloma. *Am J Ophthalmol* 2008;146:478. author reply -9.
3. Imamura Y, Iida T, Maruko I, *et al*. Enhanced depth imaging optical coherence tomography of the sclera in dome-shaped macula. *Am J Ophthalmol* 2011;151:297–302.
4. Ohno-Matsui K, Kawasaki R, Jonas JB, *et al*. International photographic classification and grading system for myopic maculopathy. *Am J Ophthalmol* 2015;159:877–83.
5. Ellabban AA, Tsujikawa A, Matsumoto A, *et al*. Three-dimensional tomographic features of dome-shaped macula by swept-source optical coherence tomography. *Am J Ophthalmol* 2013;155:320–8.
6. Ohsugi H, Ikuno Y, Oshima K, *et al*. Morphologic characteristics of macular complications of a dome-shaped macula determined by swept-source optical coherence tomography. *Am J Ophthalmol* 2014;158:162–70.
7. Chen J, Lee L. Clinical applications and new developments of optical coherence tomography: an evidence-based review. *Clin Exp Optom* 2007;90:317–35.
8. Hee MR, Puliafito CA, Wong C, *et al*. Optical coherence tomography of macular holes. *Ophthalmology* 1995;102:748–56.
9. Jarius S, Paul F, Franciotta D, *et al*. Cerebrospinal fluid findings in aquaporin-4 antibody positive neuromyelitis optica: results from 211 lumbar punctures. *J Neurol Sci* 2011;306:82–90.
10. Chebil A, Ben Achour B, Chaker N, *et al*. [Choroidal thickness assessment with SD-OCT in high myopia with dome-shaped macula]. *J Fr Ophtalmol* 2014;37:237–41.
11. García-Ben A, Kamal-Salah R, García-Basterra I, *et al*. Two- and three-dimensional topographic analysis of pathologically myopic eyes with dome-shaped macula and inferior staphyloma by spectral domain optical coherence tomography. *Graefes Arch Clin Exp Ophthalmol* 2017;255:903–12.
12. Liang IC, Shimada N, Tanaka Y, *et al*. Comparison of clinical features in highly myopic eyes with and without a dome-shaped macula. *Ophthalmology* 2015;122:1591–600.
13. Viola F, Dell'Arti L, Benatti E, *et al*. Choroidal findings in dome-shaped macula in highly myopic eyes: a longitudinal study. *Am J Ophthalmol* 2015;159:44–52.
14. Caillaux V, Gaucher D, Gualino V, *et al*. Morphologic characterization of dome-shaped macula in myopic eyes with serous macular detachment. *Am J Ophthalmol* 2013;156:958–67.
15. Ellabban AA, Tsujikawa A, Muraoka Y, *et al*. Dome-shaped macular configuration: longitudinal changes in the sclera and choroid by swept-source optical coherence tomography over two years. *Am J Ophthalmol* 2014;158:1062–70.
16. Coco RM, Sanabria MR, Alegría J. Pathology associated with optical coherence tomography macular bending due to either dome-shaped macula or inferior staphyloma in myopic patients. *Ophthalmologica* 2012;228:7–12.
17. García-Ben A, Blanco MJ, Piñeiro A, *et al*. Relationship between macular bending and foveoschisis in myopic patients. *Optom Vis Sci* 2014;91:497–506.
18. Soudier G, Gaudric A, Gualino V, *et al*. Long-term evolution of dome-shaped macula: increased macular bulge is associated with extended macular atrophy. *Retina* 2016;36:944–52.