










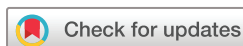BMJ Open Safety and feasibility study of non-invasive robot-assisted high-intensity focused ultrasound therapy for the treatment of atherosclerotic plaques in the femoral artery: protocol for a pilot study

Michelle V Simons ¹, Marijn H A Groen ², Gert J de Borst ³,
Tim Leiner ⁴, Pieter A F Doevendans ^{2,5}, Emad Ebbini ⁶,
Fons J B Slieker ⁷, René van Es ², Constantijn E V B Hazenberg ³

To cite: Simons MV, Groen MHA, de Borst GJ, *et al.* Safety and feasibility study of non-invasive robot-assisted high-intensity focused ultrasound therapy for the treatment of atherosclerotic plaques in the femoral artery: protocol for a pilot study. *BMJ Open* 2022;**12**:e058418. doi:10.1136/bmjopen-2021-058418

► Prepublication history and additional supplemental material for this paper are available online. To view these files, please visit the journal online (<http://dx.doi.org/10.1136/bmjopen-2021-058418>).

Received 18 October 2021
Accepted 06 April 2022



© Author(s) (or their employer(s)) 2022. Re-use permitted under CC BY-NC. No commercial re-use. See rights and permissions. Published by BMJ.

For numbered affiliations see end of article.

Correspondence to
Michelle V Simons;
michelle.valerie.simons@hotmail.com

ABSTRACT

Introduction Peripheral arterial disease (PAD) is an atherosclerotic disease leading to stenosis and/or occlusion of the arterial circulation of the lower extremities. The currently available revascularisation methods have an acceptable initial success rate, but the long-term patency is limited, while surgical revascularisation is associated with a relatively high perioperative risk. This urges the need for development of less invasive and more effective treatment modalities. This protocol article describes a study investigating a new non-invasive technique that uses robot assisted high-intensity focused ultrasound (HIFU) to treat atherosclerosis in the femoral artery.

Methods and analysis A pilot study is currently performed in 15 symptomatic patients with PAD with a significant stenosis in the common femoral and/or proximal superficial femoral artery. All patients will be treated with the dual-mode ultrasound array system to deliver imaging-guided HIFU to the atherosclerotic plaque. Safety and feasibility are the primary objectives assessed by the technical feasibility of this therapy and the 30-day major complication rate as primary endpoints. Secondary endpoints are angiographic and clinical success and quality of life.

Ethics and dissemination Ethical approval for this study was obtained in 2019 from the Medical Ethics Committee of the University Medical Center Utrecht, the Netherlands. Data will be presented at national and international conferences and published in a peer-reviewed journal.

Trial registration number NL7564.

INTRODUCTION

Peripheral arterial disease (PAD) is an atherosclerotic disease leading to stenosis and/or occlusion of the arterial circulation of the lower extremities. The severity of PAD varies from asymptomatic stenosis to limb-threatening ischaemia.^{1–3} In case of severe

Strengths and limitations of this study

- First in human study to assess the safety and feasibility of noninvasive high-intensity focused ultrasound/dual-mode ultrasound array therapy to target atherosclerotic plaques in the femoral artery.
- Extensive follow-up in the first month after the procedure with duplex ultrasound and MRI providing detailed information about the plaque response to the therapy.
- Next to quantitative plaque analysis, patients are asked to fill in quality of life questionnaires specially designed for Dutch patients with peripheral arterial disease.
- This is a non-randomised single-centre study and consequently there is chance of selection bias.
- Calcified plaques are an exclusion parameter so the data collected in this study cannot be extrapolated to the full spectrum of plaque morphologies.

symptoms, revascularisation is indicated. Three main options are generally available for revascularisation, namely, open, endovascular or a hybrid intervention. The open option is the surgical removal of the atherosclerotic plaque (endarterectomy) or bypass surgery, where a new conduit of blood flow is created to overcome the stenosis or occlusion. The endovascular option is a minimally invasive manner of increasing the lumen diameter by inflating a balloon (angioplasty) combined with expanding a metal scaffold (stent), if indicated. In a hybrid case, open surgery and endovascular surgery are combined. The predicted benefit for patients should outweigh the potential risks and durability of the intervention.^{4–6} Most peripheral arterial interventions have an

acceptable initial technical and clinical success rate, but the long-term patency is limited.⁵ Furthermore, fluoroscopy exposure during these procedures also possesses potential health risks, such as DNA damage and long-term health effects, to both the patient and the treatment team.⁷⁻⁹

Guidelines including The Trans-Atlantic Inter-Society Consensus for the Management of PAC generally recommend for revascularisation options (open, endovascular or hybrid procedures) based on the anatomical location and extent of the arterial lesions.^{4,5,10} Endovascular revascularisation is generally preferred over open procedures due to the reduced perioperative morbidity and shorter hospital stays.^{1,11} However, endovascular strategies for stenotic lesions located in anatomically 'hostile' arterial segments or 'no stent areas,' such as arterial flexion points (surrounding joints), remain a subject for debate. For example, the endovascular approach has not been adopted widely in the common femoral artery (CFA) (groin). Despite the reduction of wound-related complications and shorter hospital stay, endovascular revascularisation in the CFA is associated with a lower patency and increased rates of subsequent revascularisation procedures. Another concern is that stent placement in this region may limit access options for future procedures, and the bending forces may cause stent fracture and subsequent arterial occlusion.¹² For this reason, despite the risk of infection and septic bleeding, open endarterectomy of the CFA is still considered the gold-standard therapy.^{13,14}

An alternative to the increased complication risk of the open surgical approach is endovascular plaque debulking. With plaque debulking, the plaque is removed and reduced rather than cracked and pressed against the arterial wall, which might lessen vessel barotrauma and reduce the risk of plaque recoil. Directional, rotational, orbital and laser atherectomy are current examples of endovascular plaque debulking with good technical success rates.¹⁵ Nevertheless, the reported restenosis and subsequent reinterventions rates are comparable to regular endovascular revascularisation.¹⁵

Non-invasive plaque debulking techniques may overcome the risk of perioperative complications associated with surgery altogether. High-intensity focused ultrasound (HIFU) enables noninvasive tissue ablation.¹⁶⁻¹⁸ Dual-mode ultrasound arrays (DMUA) offers the possibility of simultaneous HIFU targeting and ultrasound (US) imaging, thereby allowing inherent registration between imaging and treatment location.¹⁹⁻²¹ HIFU/DMUA therapy can be used for transcatheter noninvasive ablation of targets with submillimeter precision and accuracy.^{17,19-24} The pathophysiology of atherosclerosis suggests that atherosclerotic plaques may respond to HIFU/DMUA therapy.²¹ It is hypothesised that the local thermal effect of HIFU causes coagulation necrosis affecting the plaque and inducing a new immune response with a complex cascade of cellular reactions, eventually leading to a decrease in plaque volume and an increased lumen diameter.^{25,26}

Table 1 DMUA technical specifications

Type	Linear array transducer
No of channels	2 rows of 32 elements
Mechanical focusing	Spherical
Radius of curvature	50 mm \pm 2 mm
Inter-element spacing	0.2 mm
Height of the elements	34 mm divided into two rows (equal height)
Frequency	3.5 MHz

DMUA, dual-mode ultrasound array.

A clinical trial currently being conducted at the University Medical Center Utrecht (UMCU) is investigating the safety and feasibility of this technique. This article describes the working protocol for the treatment of femoral arterial disease with this specific intervention.

Technical background: HIFU/DMUA synthesiser

The DMUA transducer used in this study is specifically developed for arterial plaque debulking purposes.²⁰ The 3.5 MHz 64-element concave shaped dual mode array transducer (Imasonic, Voray sur l'Oignon, France) uses the spherical shape for mechanical steering of the US beams (table 1). The transducer is attached to a 6 df robotic arm (UR3, Universal Robots, Odense, Denmark) to allow precise positioning that enables accurate imaging and treatment on a submillimetre scale.

The HIFU/DMUA synthesiser is an integrated medical device that delivers US-guided HIFU therapy (figure 1). The DMUA allows real-time monitoring of lesion formation and can therefore be used as a closed-loop feedback to control energy delivery to optimise treatment. HIFU therapy is based on the fact that US beams are partially converted into thermal energy when travelling through tissue. At low intensities, as with diagnostic US, this phenomenon does not interfere with normal physiology. However, when emitted at high intensities, US beams can produce a significant rise in temperature, leading to coagulation necrosis. With HIFU therapy, the high-intensity US beams are focused on diseased tissue, thereby




Figure 1 HIFU/DMUA set-up as used during a clinical procedure. DMUA, dual-mode ultrasound array; HIFU, high-intensity focused ultrasound.

producing localised submillimeter thermal lesions at the targeted tissue leading to coagulation necrosis. For safety measures, the HIFU/DMUA synthesiser is equipped with a closed-loop prescriptive image-guided control (CLC) algorithm. The energy delivery is monitored along the acoustic path of the beam to avoid affecting non-targeted tissues and to modulate the amplitude of the HIFU pulse based on image feedback. This feedback consists of single transmit focus (STF) imaging data that are gathered before and after every 10 ms during the HIFU bursts.²⁰ STF imaging is a method of high-speed imaging enabling monitoring of the changes at the treatment site.^{20 27}

METHODS AND ANALYSIS

Study objectives

To investigate the safety and feasibility of HIFU/DMUA therapy for the treatment of symptomatic patients with atherosclerotic plaques in the femoral artery.

Study design

The study is designed as a first-in-human pilot study that is currently being conducted by the UMCU with a cohort of 15 patients diagnosed with PAD. The protocol was finalised on 25 February 2019 and first inclusion was performed on 17 June 2019. Since then, minor changes to the protocol were made and approved by the Medical Research Ethics Committee (V.1.4). The estimated end date of the study is halfway through 2023, since there has been a significant delay due to the COVID-19 pandemic. All patients are asked to provide written informed consent. After informed consent is signed, patients will undergo a thorough screening to assess eligibility for inclusion.

Primary study parameters

The main endpoints are the safety and feasibility of this experimental treatment. Safety is determined by the 30-day major complication rate. This is a composite safety endpoint, based on previously validated safety endpoints for symptomatic PAD.^{28–30} It consists of the 30-day major adverse event (AE) rate, which is defined as any complication that requires endovascular revascularisation, open revascularisation or amputation in the target limb. Second, it consists of the 30-day mortality rate. Feasibility is defined as being able to accomplish the HIFU/DMUA procedure to target the atherosclerotic plaque in the CFA and/or superficial femoral artery (SFA).

Secondary study parameters

Secondary endpoints are defined as technical, vascular imaging, clinical and quality of life parameters. Technical success is defined as successful visualisation of the target lesion and successful delivery of HIFU therapy to the intended target lesions. During the procedure, procedural data of the device, the number, intensity and duration of all HIFU shots delivered will be recorded and analysed. The intensity of the shots is depending on the HIFU amplitude and tissue attenuation and absorption but is generally around 6.25 kW/cm².²¹

After the HIFU procedure the number of shots and the efficacy of the shots will be determined. The efficacy will be analysed based on the echogenicity change during the shot. Shots reaching threshold will be considered as effective HIFU shots. Another important aspect of the technical success is the non-occurrence of complications such as thrombosis, dissection or occlusion within the target vessel due to the HIFU therapy.

Follow-up by vascular imaging is performed with both MRI and duplex US (DUS) to visualise plaque morphology and stenosis severity over time. With MRI changes in lesion length (mm), stenosis severity (%), total plaque volume (mm³), total vascular wall volume (mm³) and atherosclerotic (peri) plaque characteristics like presence of oedema, calcification, intraplaque haemorrhage and presence of a lipid rich necrotic core can be analysed. DUS imaging will be used to assess the haemodynamic changes by measuring the peak systolic velocity ratio at the target lesion. Furthermore, plaque (surface) characteristics will be described and special attention will be given to assess the occurrence of arteriovenous fistula.

Clinical endpoints are assessed on functional exercise and the Ankle-Brachial Index (ABI) measurements. Haemodynamic success is defined as an improvement in the ABI at 30 days postprocedure compared with baseline. Functional success is defined as an improvement on exercise testing. An improvement of symptoms is also taken into account.

Patients and eligibility criteria

The present safety and feasibility study is a pilot being conducted by the UMCU, the Netherlands. To determine whether HIFU treatment is safe in this study, the safety outcome of HIFU-treatment has to be non-inferior to the safety outcome of the common femoral endarterectomy (CFE). The complication rate of a CFE varies between 6% and 26%,¹³ with the point of gravity around 8% (1 in 12.5 patients). Therefore, a sample size of 15 patients is chosen for this safety trial for the investigational therapy. The most relevant eligibility criteria are represented in table 2, the full list of eligibility criteria is added as online supplemental information. Patients classified as Fontaine class IIB or III with an isolated CFA or proximal SFA, or multilevel femoral disease (CFA and SFA) but no indication to treat distal the SFA (in case of Fontaine IIB), will be considered to be eligible for inclusion. Written informed consent is obtained during the baseline visit after a reflection period of at least 7 days after the first study information visit.

Data handling

Participant UMCU healthcare data, data from medical interviews, quality of life questionnaires and data from various medical tests and measurements are filed as source data in the electronic patient records. All study-related results from medical interviews, tests and measurements are collected in an electronic case report form (eCRF) with audit trail functionality. Internal auditing is performed and, independent from the sponsor, monitoring is performed by the Julius Clinical Research (Zeist, The Netherlands). The monitor will visit periodically to discuss progress of the clinical trial, review

Table 2 Eligibility criteria

Inclusion criteria	Exclusion criteria
Patient <85 years	Patient is diagnosed with early onset PAD
Patient is diagnosed with symptomatic PAD (ABI <0.90)	Contraindication for MRI or gadolinium contrast agent
Primary non-stented target plaque with focal stenosis in CFA/proximal SFA	Recent cardiovascular event or major surgery (<6 months ago)
Presence of lower extremity CTA imaging to measure: <ul style="list-style-type: none"> ▶ Grade of stenosis 50%–90% ▶ Plaque length ≤40 mm ▶ Grade of calcification ≤50% ▶ Distance dorsal vessel wall to the skin ≤35 mm 	Contra-indication for antiplatelet therapy
Target vessel visible with DMUA/HIFU synthesiser imaging	

ABI, Ankle–Brachial Index; CFA, common femoral artery; CTA, CT angiography; DMUA, dual-mode ultrasound array; HIFU, high-intensity focused ultrasound; PAD, peripheral arterial disease; SFA, superficial femoral artery.

correspondence and review the CRFs and the original documents with the study personnel for accuracy of data recording. Research data are stored anonymised and personal data are stored separately. A separate file is created to identify the patient via their unique study number. Research data will be archived for 15 years after the study has ended. To be able to reproduce the study findings, and to help future users understand and reuse data, all changes made to the raw data will be documented in data queries generated in the eCRF.

Study procedures

Screening procedure

The vascular surgeon identifies potential eligible study participants. If the patient consents and meets eligibility criteria as mentioned in [table 2](#) the HIFU specific plaque characteristics (arterial depth, grade of calcification and stenosis severity) will be evaluated in collaboration with a designated expert radiologist. Based on lower extremity CT angiography and DUS the calcification grade of maximal 50% in the culprit lesion and arterial depth of maximal 35 mm will be measured ([table 2](#)).

Baseline visit

During the baseline visit, patients are asked to sign the informed consent form. After this a clinical interview, physical examination, DUS and MRI, exercise test and a HIFU/DMUA visibility test is performed. The results of the baseline visit determine if a patient is definitively eligible for study participation.

Intervention

The patient is lying in supine position under sedation during the HIFU procedure. DUS is used initially to visualise and mark the target area on the skin before the HIFU procedure. Anatomical landmarks, such as the CFA/SFA bifurcation, proximal and distal end of the plaque, and calcifications, are marked on the skin as additional guidance for the treatment team during imaging with the DMUA transducer. After this the DMUA transducer is placed in the groin region from where the CFA/SFA plaque can be followed from proximal to distal and eventually targeted. Compared with conventional DUS, image resolution of the DMUA transducer is inferior

(axial resolution is ~2.6 mm and lateral resolution is ~1.2 mm while conventional DUS can reach submillimeter resolution depending imaging settings).^{27 31} For this reason, additional DUS is required in this phase to ensure correct targeting.

The transducer is attached to a 6 df robotic arm to ensure precise positioning and accurate imaging of the target area. The transducer is placed in the groin, perpendicular to the CFA to create a transversal plane through the artery. When the CFA is visualised, the robot arm is used to move the transducer along the vessel pathway to visualise the CFA bifurcation and proximal part of the SFA. During this visualisation step, synthetic aperture imaging²⁷ is used for real-time visualisation of the full trajectory. When the full trajectory is visualised and the target planes are determined, the HIFU therapy can start. Per transversal plane ([figure 2](#)) multiple shots will be delivered in the stenosis area with an inter-target distance of 1 mm. When a full plane is targeted, the robot moves the transducer 1 mm to repeat the process of targeting in the next transversal plane ([figure 2](#)). This process is repeated for 10 planes and after this the transducer is moved up to visually inspect the skin region for eventual thermal damage. When there is no sign of thermal damage the transducer can be moved back to the position and the therapy will be continued.

When the stenosis is treated in full length, the skin is again inspected for thermal damage and the lower extremity is

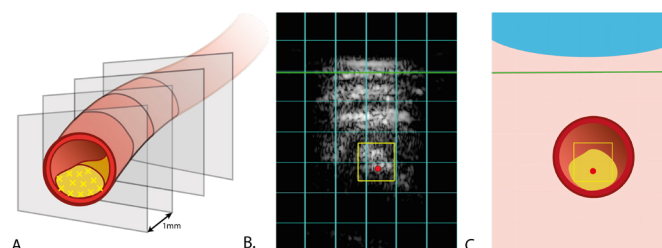


Figure 2 (A) Schematic overview of target planes in a vessel. (B) Screenshot of the DMUA/HIFU image of the vessel with target area marked by the red dot. The green box represents the skin interface and the yellow box represents the region of interest. (C) Schematic overview of the screenshot shown in panel (B). DMUA, dual-mode ultrasound array; HIFU, high-intensity focused ultrasound.

Table 3 Follow-up scheme for study participants

	Baseline	Procedure day	+1 day	+7 days	+14 days	+21 days	+30 days	+90 days
Standardised medical interview	+	+	+	+	+	+	+	+
Physical examination	+	+	+	+	+	–	+	+
Ankle Brachial Index	+	+	+	+	+	–	+	+
MRA	+	–	+		–	–	+	–
DUS	+	+	+	+	+	–	+	+
Exercise test	+	–	–	–	–	–	+	–
Quality of life questionnaire*	+	–	+	–	+	–	+	+

The + sign indicates the test is performed during the visit.

*Standardised and validated vascular quality of life questionnaires are used; VascuQoL-NL/EQ-5D-3L.⁴⁰

DUS, duplex ultrasound; MRA, Magnetic Resonance Angiography; VascuQoL-NL/EQ-5D-3L, Vascular Quality of Life Questionnaire (Dutch) / Standardized questionnaire generating a measure for health status.

assessed for any signs of distal thromboembolism or arterial occlusion. The vascular surgeon also checks for acute vascular patency with DUS.

Follow-up

The overall duration of the follow-up for study participants is 3 months at specific moments in time. Full follow-up scheme with associated tests and measurements is visible in [table 3](#). During the follow-up, patients are assessed on change in symptoms and eventual changes in the stenosis severity based on different imaging modalities (DUS, MRA). Haemodynamic changes are assessed based on the ABI and exercise test.

Monitoring

Data safety monitoring will be performed by the research team and two independent experts (both UMCU radiologists with experience in the field of MR-guided HIFU therapy), who shall function as medical safety monitors. The research team and medical safety monitors will monitor any AEE to evaluate the safety of the HIFU treatment.

Adverse events

In case of an AE, the research team will convene and discuss this within a week, to evaluate whether the AE was procedure related and to evaluate the safety of the HIFU treatment. Two independent experts will periodically (every five patients) review all AEs. In case of a serious AE (SAE), the independent experts are informed <7 days. In case of life-threatening AEs or death, the independent experts are informed <3 days.

SAEs are reported through the web portal 'ToetsingOnline' to the accredited Medical Ethics Committee that approved the protocol and to the 'Inspectie gezondheidszorg en jeugd', within 15 days after first knowledge of the SAE. SAEs resulting in death or a life-threatening situation are reported expeditiously.

All AEs are followed until they are resolved, or until a stable situation has been reached. Depending on the event, follow-up may require additional tests or medical procedures as indicated and/or referral to the general physician or a medical specialist.

Premature termination of the study is considered in case of an unexpected major procedure related SAE that results in death or near-fatal complications. The study team will meet to decide on premature termination of the study in case of frequent (>2) severe complications that, in the opinion of the study team and/or medical monitors, bring into question the safety of the procedure and therewith the safety of the other participants.

The sponsor also has an insurance which is in accordance with the legal requirements in the Netherlands (Article 7 WMO and the Measure regarding Compulsory Insurance for Clinical Research in Humans of 23 June 2003). This assurance provides cover for damage to research subjects through injury or death caused by the study. The insurance applies to the damage that becomes apparent during the study or within 4 years after the end of the study.

Statistical analysis

Statistical analysis will be performed with the Statistical Package for the Social Sciences (V.25.0 for Windows, SPSS). For the primary endpoint, the 30-day procedure-related major complication rate will be shown as a percentage by dividing the number of major complications by the number of procedures. Major procedure-related complications are defined as complications that require endovascular or open revascularisation, amputation (eg, treated segment thrombosis, acute onset of limb ischaemia), or that might lead to patient death within 30 days of the procedure.

We choose not to perform repeated measurement analyses as we are interested in demonstrating an effect in this first-in-human-use proof-of-concept study, rather than quantifying this effect. Nonetheless, most parameters of the tests and measurements will be represented as continuous variables. The plaque characteristics will be presented as categorical variables and will be analysed by means of the Fisher's exact test. Changes in these continuous variables will be analysed by means of the paired t-test or the Mann-Whitney U test, when applicable. Results of analysis will be considered significant when $p < 0.05$. Missing data will be excluded pairwise.

Patient and public involvement

Patients or the public were not involved in the design, or conduct, or reporting, or dissemination plans of our research. Participants are asked to give feedback on their experience during the conduct of the study. The participants will be informed once the trial results are published.

ETHICS AND DISSEMINATION

This study is conducted according to the principles of the Declaration of Helsinki (64th WMA General Assembly, Fortaleza, Brazil, October 2013)³² and in accordance with the Dutch Medical Research Involving Human Subjects Act (WMO). The study design was approved by the Medical Research Ethics Committee of University Medical Center Utrecht, The Netherlands. An Investigator Site File is produced in advance of the study conforming to the institutional guidelines. In case of any protocol amendments needed during the study, the Medical Ethics Committee will be notified. The results of the study are disclosed unreservedly and will be submitted to a peer-reviewed scientific journal, in accordance to the CCMO statement [<https://www.ccmo.nl/onderzoekers/klinisch-onderzoek-naar-medische-hulpmiddelen/tijdens-en-na-onderzoek-naar-medische-hulpmiddelen/resultaten-onderzoek>] containing the basic principles on the disclosure and publication of research results obtained from studies involving human subjects.

DISCUSSION

The HIFU trial is a first-in-human pilot study. The goal of the clinical trial is to investigate the safety and feasibility of robot-assisted HIFU using a DMUA for the treatment of peripheral atherosclerosis. The DMUA allows imaging and delivery of therapy with a single transducer, enabling accurate targeting and a CLC to optimise energy delivery. The local (~1 mm) thermal effect generated by focusing the high-intensity US beams is expected to affect the cycle of plaque formation as it causes coagulation necrosis.^{22 33} The hypothesis is that the generated heat causes decellularisation of the soft plaque segments and reduces the vasa vasorum.^{26 34–36} This disrupts the plaque formation, reduces the plaque volume and increases the vessel lumen diameter. The effect of HIFU therapy on atherosclerosis has only been studied in preclinical studies, and therefore, this first-in-human pilot study is conducted to assess the safety and feasibility of this therapy.

Inclusion and exclusion criteria are set to find eligible candidates for the HIFU therapy. Whether the plaque can be targeted with this specific HIFU is determined from the plaque characteristics, including plaque depth, amount of calcification and stenosis severity. The depth of the target vessel is dependent on the focus length of the DMUA transducer, which can be set between 45 and 55 mm. Because the transducer cannot be placed directly on the skin due to its concave shape, a water bolus cover is needed to enable good coupling between the skin and transducer. This dictates that the distance between the skin and the HIFU target area cannot exceed 35 mm. The bolus cover can be adjusted

to increase the distance between the transducer and skin to allow the target to be in the focal point. Furthermore, altering the pressure in the groin with the transducer can aid in getting the target within therapeutic window.

For the current study, the amount of calcific content in the culprit lesion, arterial depth and stenosis severity are essential for inclusion or exclusion. Severe calcification is considered as a contraindication for the HIFU therapy because the expected therapeutic benefit of this thermal therapy is uncertain.³⁷ Calcification is an acoustic barrier for US progression and diffusion and can potentially reflect the US beam to non-targeted tissue and therefore highly calcified lesions may not be suitable for HIFU targeting.^{37 38} Therefore, for this safety study, highly calcified lesions are contraindicated. Furthermore, in case of a stenosis grade larger than 90%, there may be a risk of occlusion due to clotting and therefore considered as contraindication. The effect of this thermal therapy on atherosclerotic plaque is unknown but in the animal studies some swelling at the targeted vascular wall was observed.^{21 39}

Plaque rupture, distal thrombosis and arterial occlusion are considered as potential complications of this therapy; however, these risks are considered to be low. Preclinical research with this experimental setup has demonstrated that the endothelium remains intact at the appropriate HIFU intensities, and no rise of temperature in the vessel wall leading to thrombosis occurred.²¹ The closed-loop feedback control is also a precaution to prevent overexposure and excessive tissue heating. The endothelial cells of the vessel wall are naturally cooled by the blood flow, thus reducing the chance of plaque rupture.²¹ The ongoing trial with this experimental therapy, however, has to demonstrate that these potential risks do not occur.

Author affiliations

¹Department of Vascular Medicine, University Medical Centre, Utrecht, The Netherlands

²Department of Cardiology, University Medical Centre, Utrecht, The Netherlands

³Vascular Surgery, University Medical Centre Speciality Surgery, Utrecht, The Netherlands

⁴Radiology, University Medical Center Imaging Division, Utrecht, The Netherlands

⁵Netherlands Heart Institute, Utrecht, The Netherlands

⁶Electrical and Computer Engineering, University of Minnesota College of Science and Engineering, Minneapolis, Minnesota, USA

⁷Department of Oral Surgery, University Medical Centre, Utrecht, The Netherlands

Contributors All authors declare to have made substantial contributions to the development of this protocol. MVS prepared the first draft of the manuscript. MHAG, RvE, CEVBH, G-JdB, PD and EE contributed to the writing, editing and revising of the protocol. FS was involved in the initial protocol drafting and submission to the Medical Ethics Research Committee. TL is responsible for patient eligibility.

Funding The HIFU study is an investigator-initiated trial. This research is supported with an unrestricted grant by the International Cardio Corporation (Edina, MN, USA), grant number not applicable. International Cardio Corporation did not have any role in the study design; in the collection, analysis and interpretation of the data; writing of the report; and in the decision to submit the paper for publication.

Competing interests CEVBH reports grants from International Cardio Corporation during the conduct of the study. He is a consultant for Cook Medical, Gore Medical, and Terumo Aortic. PD is one of the founders of the International Cardio Corporation; EE reports grants, personal fees and non-financial support from International Cardio Corporation, during the conduct of the study; grants and personal fees from International Cardio Corporation, grants and personal fees from National Institutes of Health, outside the submitted work; In addition, EE has a patent Dual

mode ultrasound transducer (DMUT) system and method for controlling delivery of ultrasound therapy with royalties paid to International Cardio Corporation, a patent Vascular characterisation using ultrasound imaging with royalties paid to International Cardio, and a patent ultrasound image formation and/or reconstruction using multiple frequency waveforms with royalties paid to International Cardio Corporation.

Patient and public involvement Patients and/or the public were not involved in the design, or conduct, or reporting, or dissemination plans of this research.

Patient consent for publication Not applicable.

Provenance and peer review Not commissioned; externally peer reviewed.

Supplemental material This content has been supplied by the author(s). It has not been vetted by BMJ Publishing Group Limited (BMJ) and may not have been peer-reviewed. Any opinions or recommendations discussed are solely those of the author(s) and are not endorsed by BMJ. BMJ disclaims all liability and responsibility arising from any reliance placed on the content. Where the content includes any translated material, BMJ does not warrant the accuracy and reliability of the translations (including but not limited to local regulations, clinical guidelines, terminology, drug names and drug dosages), and is not responsible for any error and/or omissions arising from translation and adaptation or otherwise.

Open access This is an open access article distributed in accordance with the Creative Commons Attribution Non Commercial (CC BY-NC 4.0) license, which permits others to distribute, remix, adapt, build upon this work non-commercially, and license their derivative works on different terms, provided the original work is properly cited, appropriate credit is given, any changes made indicated, and the use is non-commercial. See: <http://creativecommons.org/licenses/by-nc/4.0/>.

ORCID iDs

Michelle V Simons <http://orcid.org/0000-0003-0383-9699>

Marijn H A Groen <http://orcid.org/0000-0002-9900-6044>

Gert J de Borst <http://orcid.org/0000-0002-1389-4141>

Tim Leiner <http://orcid.org/0000-0003-1885-5499>

Pieter A F Doevendans <http://orcid.org/0000-0002-6257-7169>

Emad Ebbini <http://orcid.org/0000-0003-1334-5502>

Fons J B Sliker <http://orcid.org/0000-0002-0495-3170>

René van Es <http://orcid.org/0000-0001-9950-4388>

Constantijn E V B Hazenberg <http://orcid.org/0000-0002-2408-2720>

REFERENCES

- Thukkani AK, Kinlay S, Hospital MB. Endovascular intervention for peripheral artery disease. *Circ Res* 2015;116:1599–613.
- Bartelink MEL, Elsmann BHP, Oostindijer A. *NHG-Standaard 'Perifeer arterieel vaatlijden' (tweede herziening)*. Nederland, 2014.
- Stoner MC, Calligaro KD, Chaer RA, et al. Reporting standards of the Society for vascular surgery for endovascular treatment of chronic lower extremity peripheral artery disease. *J Vasc Surg* 2016;64:e1–21.
- Nederlandse Vereniging voor Heelkunde & Nederlandse Vereniging voor Radiologie. Richtlijn: Diagnostiek en behandeling van arterieel vaatlijden van de onderste extremiteit 2005.
- Norgren L, Hiatt WR, Dormandy JA, et al. Inter-society consensus for the management of peripheral arterial disease. *Int Angiol* 2007;26:81–157.
- AbuRahma AF. When are endovascular and open bypass treatments preferred for femoropopliteal occlusive disease? *Ann Vasc Dis* 2018;11:25–40.
- Ketteler ER, Brown KR. Radiation exposure in endovascular procedures. *J Vasc Surg* 2011;53:35S–8.
- Tang FR, Loganovsky K. Low dose or low dose rate ionizing radiation-induced health effect in the human. *J Environ Radioact* 2018;192:32–47.
- Ko S, Kang S, Ha M, et al. Health Effects from Occupational Radiation Exposure among Fluoroscopy-Guided Interventional Medical Workers: A Systematic Review. *J Vasc Interv Radiol* 2018;29:353–66.
- Madarič J, Monde P. Comment on 2017 ESC guidelines on the diagnosis and treatment of peripheral arterial diseases, in collaboration with the European Society for vascular surgery (ESVS). *Cardiology Letters* 2018;27:171–3.
- Vartanian SM, Conte MS. Surgical intervention for peripheral arterial disease. *Circ Res* 2015;116:1614–28.
- Jia X, Sun ZD, Patel JV, et al. Systematic review of endovascular intervention and surgery for common femoral artery atherosclerotic disease. *Br J Surg* 2019;106:13–22.

- Halpin D, Erben Y, Jayasuriya S, et al. Management of isolated atherosclerotic stenosis of the common femoral artery: a review of the literature. *Vasc Endovascular Surg* 2017;51:220–7.
- TASC Steering Committee, Jaff MR, White CJ, et al. An update on methods for revascularization and expansion of the TASC lesion classification to include below-the-knee arteries: a supplement to the Inter-Society consensus for the management of peripheral arterial disease (TASC II). *Vasc Med* 2015;20:465–78.
- Katsanos K, Spiliopoulos S, Reppas L, et al. Debulking atherectomy in the peripheral arteries: is there a role and what is the evidence? *Cardiovasc Interv Radiol* 2017;40:964–77.
- Elhelf IAS, Albahar H, Shah U, et al. High intensity focused ultrasound: the fundamentals, clinical applications and research trends. *Diagn Interv Imaging* 2018;99:349–59.
- ter Haar G. HIFU tissue ablation: Concept and devices. In: *Advances in experimental medicine and biology*, 2016: 3–20.
- Maloney E, Hwang JH. Emerging HIFU applications in cancer therapy. *Int J Hyperthermia* 2015;31:302–9.
- Liu D, Casper A, Haritonova A. Adaptive lesion formation using dual mode ultrasound array system. *AIP Conference Proceedings* 2017.
- Casper AJ, Liu D, Ballard JR, et al. Real-Time implementation of a dual-mode ultrasound array system: in vivo results. *IEEE Trans Biomed Eng* 2013;60:2751–9.
- Groen MHA, Sliker FJB, Vink A, et al. Safety and feasibility of arterial wall targeting with robot-assisted high intensity focused ultrasound: a preclinical study. *Int J Hyperthermia* 2020;37:903–12.
- Shehata IA, Ballard JR, Casper AJ, et al. Feasibility of targeting atherosclerotic plaques by high-intensity-focused ultrasound: an in vivo study. *J Vasc Interv Radiol* 2013;24:1880–7.
- Aravalli RN, Helden DV, Liu D, et al. Precision targeted ablation of fine neurovascular structures in vivo using dual-mode ultrasound arrays. *Sci Rep* 2020;10:9249.
- Ebbini ES, ter Haar G. Ultrasound-Guided therapeutic focused ultrasound: current status and future directions. *Int J Hyperthermia* 2015;31:77–89.
- Roti Roti JL. Cellular responses to hyperthermia (40–46 degrees C): cell killing and molecular events. *Int J Hyperthermia* 2008;24:3–15.
- Okada M, Hasebe N, Aizawa Y, et al. Thermal treatment attenuates neointimal thickening with enhanced expression of heat-shock protein 72 and suppression of oxidative stress. *Circulation* 2004;109:1763–8.
- Ebbini ES, Yao H, Shrestha A. Dual-Mode ultrasound phased arrays for image-guided surgery. *Ultrason Imaging* 2006;28:65–82.
- Patel MR, Conte MS, Cutlip DE, et al. Evaluation and treatment of patients with lower extremity peripheral artery disease: consensus definitions from peripheral academic research Consortium (PARC). *J Am Coll Cardiol* 2015;65:931–41.
- Conte MS. Understanding objective performance goals for critical limb ischemia trials. *Semin Vasc Surg* 2010;23:129–37.
- Goodney PP, Schanzer A, Demartino RR, et al. Validation of the Society for vascular surgery's objective performance goals for critical limb ischemia in everyday vascular surgery practice. *J Vasc Surg* 2011;54:100–8.
- Ng A, Swanevelder J. Resolution in ultrasound imaging. *Continuing Education in Anaesthesia Critical Care & Pain* 2011;11:186–92.
- World Medical Association. World Medical association Declaration of Helsinki: ethical principles for medical research involving human subjects. *JAMA* 2013;310:2191–4.
- Palyga I, Palyga R, Mlynarczyk J, et al. The current state and future perspectives of high intensity focused ultrasound (HIFU) ablation for benign thyroid nodules. *Gland Surg* 2020;9:S95–104.
- Moore KJ, Tabas I. Macrophages in the pathogenesis of atherosclerosis. *Cell* 2011;145:341–55.
- Sluimer JC, Gasc J-M, van Wanroij JL, et al. Hypoxia, hypoxia-inducible transcription factor, and macrophages in human atherosclerotic plaques are correlated with intraplaque angiogenesis. *J Am Coll Cardiol* 2008;51:1258–65.
- Sedding DG, Boyle EC, Demandt JAF, et al. Vasa vasorum angiogenesis: key player in the initiation and progression of atherosclerosis and potential target for the treatment of cardiovascular disease. *Front Immunol* 2018;9:706.
- Copelan A, Hartman J, Chehab M, et al. High-Intensity focused ultrasound: current status for image-guided therapy. *Semin Intervent Radiol* 2015;32:398–415.
- Mearini L, Porena M. Transrectal high-intensity focused ultrasound for the treatment of prostate cancer: past, present, and future. *Indian J Urol* 2010;26:4–11.
- Ballard JR, Casper AJ, Liu D. Dual-Mode ultrasound arrays for image-guided targeting of atheromatous plaques. *AIP Conference Proceedings* 2012;1503:124–8.



- 40 van LNJ, der KETWvan. Validatie vascular quality of life Questionnaire-6-NL (VASCUQOL-6-NL). *Dutch Institute For CLinical Auditing*;18.

Inclusion criteria

In order to be eligible to participate in this study, a subject must meet all of the following criteria:

1. Maximal age of the patient is 85 years.
2. Individual is diagnosed with symptomatic peripheral arterial disease (ankle brachial index <0.9), with focal localisation in the femoral artery.
3. Individual has a non-stented, primary target lesion with a 50-90% occlusion or symptoms with a total lesion length of ≤ 40 mm.
4. Presence of CTA-imaging of the target lesion in the patient's medical file at baseline (<2 year old), from which the degree of plaque calcification can be measured.
5. On the CTA imaging an estimation of the arterial depth can be obtained. If the measured distance exceeds 35 mm proposed is to assess available duplex-ultrasound imaging for arterial depth measurement. The pressure of the ultrasound probe used during a duplex is comparable with the generated probe pressure during HIFU therapy.
6. The target vessel and/or lesion must be visible on ultrasound-imaging of the DMUA/HIFU-system.

Exclusion criteria

A potential subject who meets any of the following criteria will be excluded from participation in this study:

1. Patient is diagnosed with early onset peripheral arterial disease.
2. The maximum distance from the skin surface to the dorsal vessel wall exceeds 35 mm based on ultrasound imaging.
3. The research team is unable to locate the target vessel/lesion with ultrasound-imaging of the DMUA/HIFU-system.
4. Volume of calcified areas in the plaque more than 50% of the culprit lesion, and/or distribution of calcification in the culprit lesion which the research team considers not suitable for HIFU-treatment after preprocedural assessment of the existing CTA-imaging.
5. Plaque that in the opinion of the research team is unsuitable for HIFU-treatment after baseline screening of patients with MRA and/or echo-duplex. For example, unstable plaque (e.g. thin fibrous cap, or intraplaque haemorrhage).
6. Presence of any anatomical structures located near the focus of the HIFU beam, which in the opinion of the study team, would interfere with safe delivery of the therapy (e.g. nerves, bone, extensive scar tissue).
7. History of prior femoral artery stenting at the contemplated target location.

8. Recent (<6 months) cardiovascular event (myocardial infarction, unstable angina pectoris, TIA/CVA) or major surgery.
9. Contraindication for antiplatelet therapy.
10. Any serious medical condition or any other (medical, physical, anatomical) considerations, which in the opinion of the study team may adversely affect the safety of the participant in the study.
11. Individual has any contraindications for any of the study investigations (e.g. claustrophobia for MRI).
12. Individual has a known, unresolved history of substance abuse or alcohol dependency, lacks the ability to comprehend or follow instructions or would be unlikely or unable to comply with the study protocol.
13. Individual is currently enrolled in another investigational or device trial.
14. Individual is pregnant, nursing or planning to be pregnant.