

Mansonella ozzardi corneal lesions in the Amazon: a cross-sectional study

Lucas Monferrari Monteiro Vianna,¹ Marilaine Martins,² Marcos Jacob Cohen,³ Jacob Moyses Cohen,³ Rubens Belfort Jr¹

To cite: Vianna LMM, Martins M, Cohen MJ, *et al.* *Mansonella ozzardi* corneal lesions in the Amazon: a cross-sectional study. *BMJ Open* 2012;**2**:e001266. doi:10.1136/bmjopen-2012-001266

► Prepublication history and additional material for this paper are available online. To view these files please visit the journal online (<http://dx.doi.org/10.1136/bmjopen-2012-001266>).

Received 22 April 2012
Accepted 18 October 2012

This final article is available for use under the terms of the Creative Commons Attribution Non-Commercial 2.0 Licence; see <http://bmjopen.bmj.com>

¹Department of Ophthalmology, Vision Institute, UNIFESP, Hospital São Paulo—Federal University of São Paulo, São Paulo, São Paulo, Brazil

²Department of Parasitology, Fundação de Medicina Tropical do Amazonas, Universidade do Estado do Amazonas, Manaus, Amazonas, Brazil

³Department of Ophthalmology, Universidade Federal do Amazonas (UFAM)/Instituto de Oftalmologia de Manaus (IOM), Manaus, Amazonas, Brazil

Correspondence to

Dr Lucas Monferrari Monteiro Vianna;
lucasmvianna@yahoo.com.br

ABSTRACT

Objectives: To characterise and confirm the presence of *Mansonella ozzardi* microfilariae in the cornea by biomicroscopy and corneal confocal microscopy.

Design: Cross-sectional study.

Settings: Clinical practice study in patients from rural communities in Coari city on the Solimões river, Amazonas state, Brazil.

Participants: The eyes of 212 consecutive volunteer patients were examined using a flash light and their blood checked for the presence of microfilariae by an expert microscopist. Patients with suspicious corneal lesions (characterised as nummular keratitis) were submitted to biomicroscopy, funduscopy and corneal confocal microscopy evaluation (CCME). In two patients, a biopsy of the limbal conjunctiva adjacent to the nummular keratitis was carried out and blood collected from the surgical wound for microfilariae investigation by thick blood film examination.

Primary and secondary outcome measures: Positive correlation between corneal biomicroscopic and confocal lesions and *M ozzardi* microfilaremia.

Results: Of the 212 patients, 56 (26.4%) were positive for microfilaremia. 22 patients with nummular keratitis identified under flash light examination underwent biomicroscopy and CCME. Corneal lesions were positively correlated to microfilaremia ($p=0.0001$). At biomicroscopy, lesions were classified as quiescent or active. At CCME, lesions were categorised as circular or filiform. The associations between corneal lesions, CCME findings and microfilaremia are shown.

Conclusions: We describe *M ozzardi* microfilariae in the cornea and the associated eye pathology. Further studies using ocular tissue PCR and other imaging techniques would be helpful.

INTRODUCTION

Hundreds of types of filariae have been described. *Mansonella ozzardi* is one of the few causing infection in humans and was first reported as being associated with corneal disease in 1998.¹ *M ozzardi* is a filaria exclusively found in the America continent and one of the causes of mansonelliasis.² In Brazil it is found in the states of Roraima, Mato Grosso and Amazonas.^{3–5} The

ARTICLE SUMMARY

Article focus

- To describe corneal lesions associated with *Mansonella ozzardi* microfilaremia.
- To describe corneal confocal microscopy images in *M ozzardi* microfilaremia.
- To correlate ophthalmological clinical signs with the presence of microfilaremia in some patients.

Key messages

- Biomicroscopic investigation and corneal confocal microscopy can identify *M ozzardi* microfilariae in the cornea.
- *M ozzardi* microfilaria can be pathogenic to the eye.
- Further studies using ocular tissue PCR and other imaging techniques would be helpful.

Strengths and limitations of this study

- The study describes a very common but under-studied disease in a remote area of Brazil.
- This is the first description of *M ozzardi* corneal lesions using confocal microscopy.
- A major limitation is the absence of a control group and follow-up of patients due to field access difficulties.

microfilariae of *M ozzardi* are found in peripheral blood and can be identified by their morphological characteristics or by molecular biology.^{6–11}

The clinical features of mansonelliasis are not well described. Infected individuals are generally asymptomatic or have signs and symptoms common to other infections such as fever, cold legs, joint pain and headache.¹² Signs and symptoms may also include skin and ocular lesions^{1 13 14} and be associated with *Wolbachia*, which are bacterial endosymbionts of insects and many filarial nematodes and whose products trigger inflammatory responses.¹⁴

Coari city on the Solimões river (04°08'S, 63°07'W) has a high prevalence of *M ozzardi* infection. Studies showed an average infection rate of between 13.3% and 18.9%, with a higher prevalence in rural areas and older patients.^{2 14} Other studies conducted

in non-endemic areas found no *M ozzardi* infection.¹⁵ Onchocerciasis is not found in this region of the Amazon.¹⁶

The objective of the present study is to characterise and confirm the presence of *M ozzardi* microfilariae in the cornea and to demonstrate the positive correlation between corneal biomicroscopic and confocal lesions and *M ozzardi* microfilaremia.

METHODS

This was a cross-sectional, clinical practice study of 212 consecutive volunteer patients from rural communities of Coari city on the Solimões river, Amazonas state, Brazil, examined in August 2010. All patients had their eyes examined using a flash light and their blood checked for the presence of microfilariae by an expert microscopist. Peripheral blood infection by *M ozzardi* was determined by light microscopy examination (200× and 400×) of Giemsa-stained thick smears of peripheral blood obtained by digital puncture with a sterile disposable lancet,⁶ Knott and polycarbonate membrane filtration and by a new identification protocol using PCR (M Martins *et al*, unpublished observations).

Patients with nummular keratitis, similar to those previously described in the literature,^{1 13 14} at unilateral or bilateral eye examination were subjected to bilateral biomicroscopy, funduscopy and corneal confocal microscopy evaluation (CCME) using the Rostock Cornea Module of the Heidelberg Retina Tomograph. Slit lamp photographs were taken. The CCME was performed on the central cornea of both eyes and on the corneal regions affected by nummular keratitis.

Table 1 Association between corneal lesions and microfilaremia detected by Giemsa staining, Knott or polycarbonate membrane filtration and/or PCR*

	Corneal lesions		
	Positive (+)	Negative (–)	Total
Microfilaremia			
Positive (+)	14 (63.6%)	42 (22%)	56
Negative (–)	8 (33.4%)	148 (88%)	156
Total	22	190	212 (100%)

*p=0.0001.

Two patients underwent biopsy of the limbal conjunctiva adjacent to the area of nummular keratitis and blood was collected from the surgical wound for microfilariae investigation by thick blood film examination.

Inclusion criteria were volunteering for a blood check for *M ozzardi* microfilaremia and signing the informed consent form or have it signed by a legal representative. Exclusion criteria were not volunteering or unable to sign the informed consent form.

This was a prospective study and was approved by the UNIFESP Ethics Committee (number 0767/10). All participants signed the protocol's informed consent form.

Data were presented in contingency tables and Fisher's exact test was used to compare proportions. p Values less than 0.05 were considered statistically significant. Analyses were carried out in Stata V.11 (College Station, Texas, USA).

RESULTS

Of the 212 patients, 56 (26.4%) were positive for microfilaremia. Twenty two patients with nummular keratitis

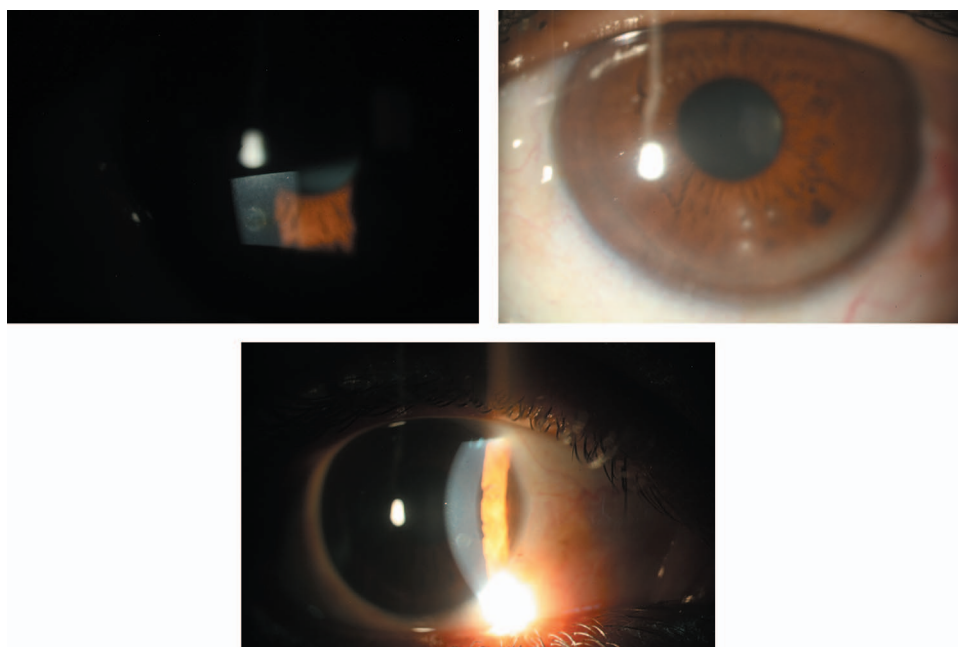


Figure 1 Clinical features. (Left and bottom) Central irregular 'mottled' appearance surrounded by an opaque halo; (right) four typical keratitis lesions with a normal translucent area between the lesions and the limbus, but no corneal neovascularisation.

Table 2 Association between corneal lesions and microfilaremia detected by Giemsa staining, Knott or polycarbonate membrane filtration and/or PCR*

	Corneal lesions		
	Keratitis	Opacities	Total
Microfilaremia			
Positive (+)	10 (76.9%)	4 (44%)	14
Negative (–)	3 (23.1%)	5 (56%)	8
Total	13	9	22 (100%)

*p=0.1347.

identified by flash light examination underwent biomicroscopy and CCME. Four of the patients had bilateral lesions. The statistically significant association between microfilaremia and corneal lesions is shown in table 1 (p=0.0001).

At biomicroscopy, some lesions were characterised as nummular, mid periphery and anterior stromal corneal opacities, 0.5–1.0 mm in diameter with a central mottled appearance surrounded by an opaque halo, and with a marked boundary between the white opacity and the clear cornea. Other lesions were characterised by nummular keratitis, also located at the mid periphery and anterior stroma. In all cases there was a normal translucent area between the corneal lesions and the limbus and an absence of corneal neovascularisation or other changes (figure 1). The clinical characteristics of the lesions as well as their high prevalence exclude the possibility of trauma or other known causes of the differential diagnosis, specifically onchocerciasis. The association between nummular keratitis and microfilaremia is shown in table 2 (p=0.1347).

Among the 22 patients with corneal lesions at biomicroscopy, 12 also had suspected related lesions at CCME. These confocal suspected lesions displayed two patterns: circular (increased reflectivity, measuring about 80 µm in diameter, located at the sub-epithelial level, as shown in figure 2) and linear (filiform lesions 250–300 µm in length and 10–15 µm in width, with one ‘C’-shaped end and the other tapered, as shown in figure 3). Five patients had only circular lesions, one patient had only linear lesions and six patients had both. The association between confocal lesions and microfilaremia is shown in table 3 (p=0.4266).

Examination of thick blood smears from the limbal conjunctiva in two patients with linear lesions confirmed microfilaremia. Figure 4 compares the *M ozzardi* microfilaria seen in the thick blood smear with the confocal microscopy image.

DISCUSSION

There is a high prevalence of *M ozzardi* in some riverside communities in the Amazon with the increasing occupation of the rainforest.^{2 16} Previous studies in Coari city showed average infection rates of between 13.3% and 18.9%, with a higher prevalence in rural areas and older patients.^{2 14} Other studies conducted in non-endemic areas show no *M ozzardi* infection.¹⁵ Prevalence was 26.4% in the present study.

Presumed keratitis caused by *M ozzardi* has also been described in Brazil by previous authors, with no other associated aetiology being identified.^{1 13 14} Comparison with other filarial diseases shows some similarities with onchocerciasis, but onchocerciasis has a different clinical picture and is rare in Brazil: it has different microfilaria tail characteristics and is only found in the Yanomami Indian Reservation close to the Venezuelan border.^{17 18} None of the patients had lived in or visited *Onchocerca* areas.

A study conducted in Pauini on the Purus river identified 20 non-Indian habitants with peripheral corneal opacities among 524 patients examined. No microfilariae were seen in the skin snips and *Mansonella* sp. was only found in the blood of the two patients from whom it was possible to collect blood.¹ Another study conducted in São Gabriel da Cachoeira (on the Negro river) showed a positive association between *M ozzardi* and corneal lesions as patients with ocular changes also had *M ozzardi* microfilariae in blood samples.¹³ However, all skin biopsies were negative for microfilaria including *Onchocerca*. Cohen *et al* also reported a positive relationship between keratitis and microfilaremia in the Amazon.¹⁴ This association was also found to be statistically significant in our study, as shown in table 1 (p=0.0001).

Corneal lesions were classified as either corneal opacities or keratitis, as shown in figure 1. Keratitis was more common among patients positive for microfilaremia, while corneal opacity was more common among patients

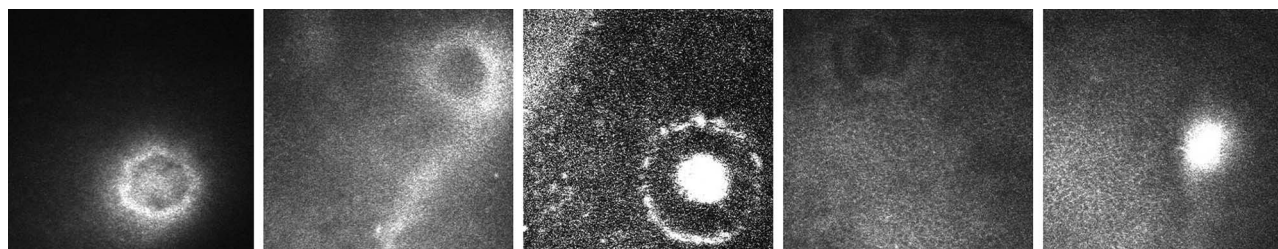


Figure 2 Five different sub-epithelial circular lesions (about 80 µm in diameter) in different patients. Images are 400 µm×400 µm.

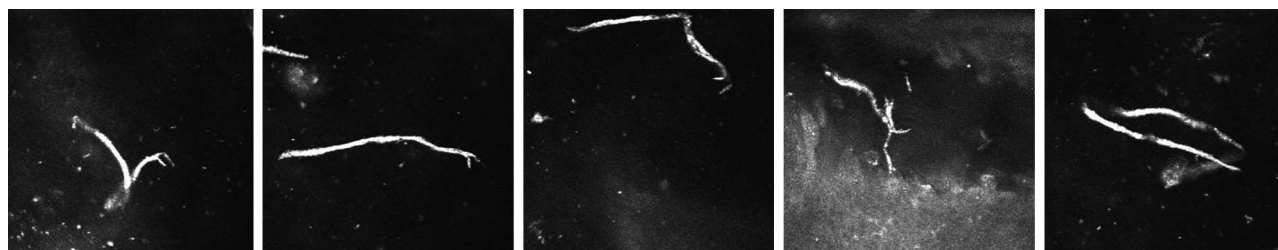


Figure 3 Filiform lesions located above the epithelium basal layer about 300 µm long and 10 µm wide, with one 'C'-shaped end and the other tapered, all in the same patient, who had a limbal conjunctiva thick blood smear positive for *Mansonella ozzardi*. Images 400 µm×400 µm.

negative for microfilaria, but neither finding was statistically significant (table 2, $p=0.1347$). One explanation for negative microfilaremia in patients with keratitis could be false negative blood tests, while chronic infection may explain the finding of microfilaremia in patients with corneal opacity.

As in previous studies,^{1 13 14} we were unable to detect filariae by biomicroscopy in any ocular tissue, but corneal lesions similar to those previously described were found. Using CCME, we detected lesions which had not been previously reported. Patients positive for microfilaremia had a higher proportion of confocal lesions (table 3, $p=0.4266$). Confocal lesions were categorised as linear or circular. More patients with lesions identified by CCME were positive for microfilaremia and more patients negative for microfilaremia had circular lesions, although this was not statistically significant (table 3, $p=0.4266$). This suggests that linear lesions are associated with active disease and circular lesions with inflammatory scars, associated or not with active disease. Linear lesions were larger (250–300 µm) on CCME than in microbiological studies (149–240 µm).⁶ The microfilariae seen in ocular tissue are probably dead and could have been enlarged due to an inflammatory reaction. In addition, circular lesions could be cross-sections of the remnants of adult worms (26–49 mm in length by 0.7–0.15 mm in diameter).⁶

Unaffected patients were not tested because of field-work difficulties. We carried out confocal microscopy in

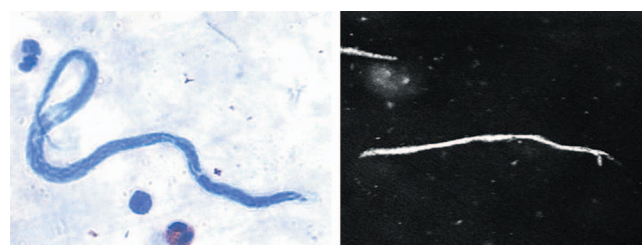


Figure 4 Microfilaria as detected by thick blood smear and corneal confocal image from a patient who underwent both tests.

both eyes of all 22 patients with keratitis. In the 18 with unilateral keratitis, the non-affected eye showed no alterations on confocal microscopy.

New molecular biology techniques for *M ozzardi* identification^{6–11} could be helpful in future PCR studies of ocular tissue to confirm the association between microfilaremia and ocular lesions.

CONCLUSION

We describe *M ozzardi* microfilariae in the cornea and the associated eye pathology. Further studies using ocular tissue PCR and other imaging techniques would be helpful.

Acknowledgements We wish to thank the following members of the Mansonella-Brazil Group: M Borborema, P Cunha, G Fontes, JF Medeiros, FAC Pessoa and T Zanelato. We also thank Nakano EM for helping with confocal microscopy analysis.

Contributors LMMV and RBJ participated in the conception and design of the study, and drafted and wrote the manuscript. LMMV, RBJ, JMC, MJC and MM participated in the collection, analysis and interpretation of data, and in the revision and final approval of the manuscript.

Funding FAPESP (Fundação de Amparo à Pesquisa do Estado de São Paulo or Foundation for Research Support of São Paulo State) funded this study.

Competing interests None.

Ethics approval UNIFESP Ethics Committee (number 0767/10) approved this study.

Table 3 Association between confocal lesions and microfilaremia (detected by Giemsa staining, Knott or polycarbonate membrane filtration and/or PCR)*

	Confocal lesions		Total
	Positive (+), circular/linear/both	Negative (–)	
Microfilaremia			
Positive (+)	2 (25%)/1 (12.5%)/5 (62.5%)	6	14
Negative (–)	3 (75%)/0/1 (25%)	4	8
Total	12	10	22

* $p=0.4266$.

Data sharing statement Further information such as population data and additional images of ophthalmological examination (biomicroscopy and confocal microscopy) can be obtained from the corresponding author.

Provenance and peer review Not commissioned; externally peer reviewed.

REFERENCES

1. Branco BC, Chamon W, Belfort R, *et al.* Ocular findings in Pauini (Southwest of the Brazilian Amazon) and possible corneal lesions caused by *Mansonella*. *Arq Bras Oftalmol* 1998;61:647–82.
2. Martins M, Pessoa FA, de Medeiros MB, *et al.* *Mansonella ozzardi* in Amazonas, Brazil: prevalence and distribution in the municipality of Coari, in the middle Solimões River. *Mem Inst Oswaldo Cruz* 2010;105:246–53.
3. Deane MP. Sobre a incidência de filárias humanas em Manaus, estado do Amazonas. *Rev Serv Esp Saude Publ* 1949;2:849–58.
4. Oliveira wr. (Filarial infestation in inhabitants of Vila Pereira, territory of Roraima (Brazil)). *Rev Inst Med Trop Sao Paulo* 1963;5:287–8.
5. D'Andretta Jr C, Pio da Silva CM, Kameyana F. Ocorrência da mansonelose entre índios do alto Xingu. *Rev Soc Bras Med Trop* 1969;3:11.
6. Orihel TC, Eberhard ML. *Mansonella ozzardi*: a redescription with comments on its taxonomic relationships. *Am J Trop Med Hyg* 1982;31:1142–7.
7. Morales-Hojas R, Post RJ, Shelley AJ, *et al.* Characterisation of nuclear ribosomal DNA sequences from *Onchocerca volvulus* and *Mansonella ozzardi* (Nematoda: Filarioidea) and development of a PCR-based method for their detection in skin biopsies. *Int J Parasitol* 2001; 31:169–77. Erratum in: *Int J Parasitol* 2001;31(8):850–1.
8. Vera LJ, Basano S de A, Camargo J de S, *et al.* Improvement of a PCR test to diagnose infection by *Mansonella ozzardi*. *Rev Soc Bras Med Trop* 2011;44:380–2.
9. Tang TH, López-Vélez R, Lanza M, *et al.* Nested PCR to detect and distinguish the sympatric filarial species *Onchocerca volvulus*, *Mansonella ozzardi* and *Mansonella perstans* in the Amazon Region. *Mem Inst Oswaldo Cruz* 2010;105:823–8.
10. Degeese MF, Cabrera MG, Krivokapich SJ, *et al.* Contribution of the PCR assay to the diagnosis of *Mansonella ozzardi* in endemic areas of Argentina. *Rev Argent Microbiol* 2012;44:97–100. Spanish.
11. Marcos LA, Arrospide N, Recuenco S, *et al.* Genetic characterization of atypical *mansonella* (*Mansonella*) *ozzardi* microfilariae in human blood samples from Northeastern Peru. *Am J Trop Med Hyg* 2012;87:491–4.
12. Batista D, Cerqueira NL, Moraes MA. (Epidemiology of Manson's disease in a locality in the interior of Amazonas). *Rev Assoc Med Bras* 1960;6:176–84.
13. Garrido C, Campos M. First report of presumed parasitic keratitis in Indians from the Brazilian Amazon. *Cornea* 2000;19:817–19.
14. Cohen JM, Ribeiro JA, Martins M. Ocular manifestations in mansonelliasis. *Arq Bras Oftalmol* 2008;71:167–71. Portuguese.
15. Basano S de A, Camargo J de S, Vera LJ, *et al.* Investigation of the occurrence of *Mansonella ozzardi* in the State of Rondônia, Western Amazonia, Brazil. *Rev Soc Bras Med Trop* 2011;44:600–3.
16. Medeiros JF, Py-Daniel V, Barbosa UC, *et al.* (Occurrence of *Mansonella ozzardi* (Nematoda, Onchocercidae) in riverine communities of the Purus river, Boca do Acre municipality, Amazonas State, Brazil). *Cad Saude Publica* 2009;25:1421–6.
17. Belfort Jr R, Moraes. M—Onchocercose ocular no Brasil. *AMB Rev Assoc Med Bras* 1979;25:123–7.
18. Sauerbrey M. The Onchocerciasis Elimination Program for the Americas (OEPA). *Ann Trop Med Parasitol* 2008;102 Suppl 1:25–9.